

Medical Cases and Topics for Health Care Providers are based upon inquiries received by NPIC, as well as relevant publications in the scientific literature. They are intended to educate health care providers about pesticide toxicology.

## Synthetic Pyrethroids and Paresthesias

### Scenario:

A 58-year old adult male with a history of well-controlled insulin dependent diabetes visits his health care provider for current symptoms of tingling and numbness on the fingers and dorsum of the hands. The symptoms developed 12 hours before the office visit. The patient reports that the symptoms worsen when he washes his hands with warm water. He has no other symptoms. He has had similar episodes of tingling and numbness of the hands on 3 occasions in the past several months. On each occasion, the tingling and numbness occurred in different areas of the hands. In the past, the symptoms have resolved after 12-24 hours.

On examination, the patient appears healthy. Inspection of the hands does not reveal signs of rash, erythema, or edema. The hands are warm, with good peripheral pulses and capillary refill. Neurological examination reveals a slight decrease in sensation to light touch in the index finger of the right hand, and the dorsum of the thumb and index finger of the left hand. When testing for temperature sensation, the patient reports an exacerbation of symptoms after a warm stimulus. Phalen's test and Tinel's sign are negative. Neurological examination of the lower extremities and the remainder of the physical examination is unremarkable.

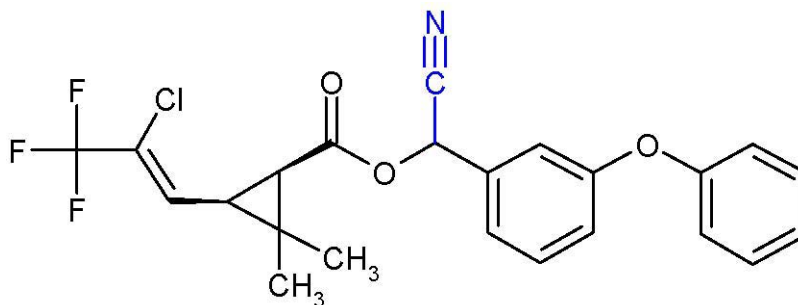
Blood work is conducted, revealing a hemoglobin A1c of 6.3% (indicating good control of blood sugar). A dipstick urinalysis is positive for trace levels of protein. The health care provider is concerned about the development of peripheral neuropathy, and schedules the patient for nerve conduction studies and a follow-up appointment to re-assess his current diabetes treatment regimen. The patient cancels the follow-up appointment after his symptoms resolve within 24 hours of the office visit.

---

### Discussion:

This case demonstrates the importance of an occupational and environmental exposure history, as the signs and symptoms of acute exposure to certain pesticides can be similar to common medical conditions. In this case the patient was a cabbage farmer, whose skin had been exposed to the insecticide lambda-cyhalothrin on several occasions throughout the growing season. When additional questions were asked in relation to exposures during his farming activities, it was discovered that the farmer had experienced several instances of direct skin contact with a concentrated insecticide formulation containing lambda-cyhalothrin as active ingredient. The exposures occurred when he was mixing and transferring the liquid without the use of appropriate skin protective measures. An expanded occupational history led to the correct diagnosis and an opportunity to reduce and prevent unnecessary exposure.

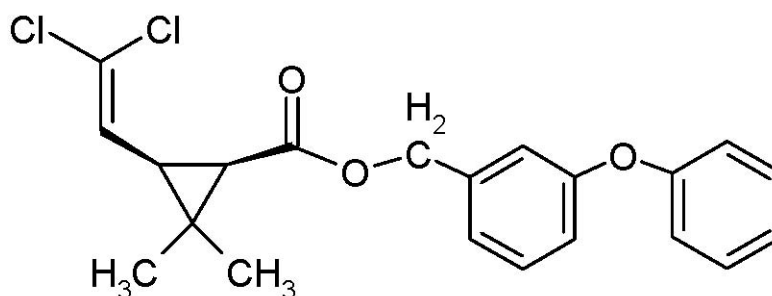
Figure 1: Chemical structure of lambda-cyhalothrin (alpha-cyano group in blue)



Lambda-cyhalothrin (Figure 1) is an insecticide that is registered for use in the United States by the Environmental Protection Agency. It is within a class of insecticides known as synthetic pyrethroids. Synthetic pyrethroids affect the nervous system of insects by prolonging the deactivation of voltage-gated sodium channels, which results in prolonged excitation of nerve fibers.<sup>1</sup> There is evidence that synthetic pyrethroids containing an alpha-cyano group (such as lambda-cyhalothrin) are more potent in eliciting neurotoxic effects, in comparison to pyrethroids that do not contain an alpha-cyano group (such as permethrin, Figure 2, below).<sup>1,2</sup>

While synthetic pyrethroids have a higher level of selectivity and toxicity for the insect nervous system, local effects on human skin resulting in paresthesias can occur in association with overexposure. Systemic intoxication is uncommon in humans, as the dermal absorption of these chemicals appears to be minimal.<sup>3,4</sup> Most cases of systemic poisoning and central nervous system effects from synthetic pyrethroids have been reported in association with occupational overexposure and from intentional ingestion.<sup>5</sup>

Figure 2: Chemical structure of permethrin



Individuals at higher risk of cutaneous exposure to synthetic pyrethroids include workers involved in the application of these compounds.<sup>5,6</sup> Activities associated with a potential for direct contact with synthetic pyrethroids include transferring, mixing, and diluting concentrated formulations. Cutaneous exposure can also occur from moving through vapor or mist at or around the time of application.

For more information contact: NPIC

Oregon State University, 310 Weniger Hall, Corvallis, OR 97331-6502

Phone: 1-800-858-7378 Fax: 1-541-737-0761

Email: [npic@ace.orst.edu](mailto:npic@ace.orst.edu) Web: [npic.orst.edu](http://npic.orst.edu)

Field studies of agricultural workers with cutaneous exposure to synthetic pyrethroids have reported that when paresthesias occur, the abnormal sensations usually develop several hours after the time of contact. The paresthesia has been described as ranging from a mild itch to a stinging sensation, with progression to numbness in some cases. These paresthesias can be exacerbated by direct exposure to sunlight and upon contact with water.<sup>6</sup> The duration of symptoms varies, ranging from several hours to approximately 24 hours.<sup>7</sup> In most cases there are no physical abnormalities (such as erythema, edema, or vesiculation) observed in areas of affected skin.<sup>6,7</sup> In a study that investigated abnormalities in neurological signs and electrophysiological findings among individuals who had experienced paresthesias from contact exposure to synthetic pyrethroids, no significant differences were observed in comparison to unexposed (control) subjects.<sup>8</sup>

Paresthesias are considered a local effect resulting from cutaneous overexposure to certain synthetic pyrethroids, in contrast to an effect mediated through the central nervous system.<sup>9</sup> Experimental studies and anecdotal reports have suggested that topical Vitamin E (alpha-tocopherol) can reduce the effect of paresthesias through mechanisms that are not well-understood.<sup>10,11</sup> The use of such treatments should not be considered a substitute for other means of reducing unnecessary exposure including engineering controls, education and training of pesticide applicators as required under the Worker Protection Standard, and appropriate use of personal protective equipment consistent with the pesticide product labeling.

## References

1. Soderlund DM, Clark JM, Sheets LP, Mullin LS, Piccirillo VJ, Sargent D, Stevens JT, Weiner ML. Mechanisms of pyrethroid neurotoxicity: implications for cumulative risk assessment. *Toxicology* 2002, 171: 3-59.
2. Flannigan SA, Tucker SB, Key MM, Ross CE, Fairchild EJ, Grimes BA, Harrist RB. Synthetic pyrethroid insecticides: a dermatological evaluation. *Br J Ind Med* 1985, 42: 363-372.
3. Woollen BH, Marsh JR, Laird WJ, Lesser JE. The metabolism of cypermethrin in man: differences in urinary metabolite profiles following oral and dermal administration. *Xenobiotica* 1992, 22: 983-991.
4. Williams RL, Bernard CE, Krieger RI. Human exposure to indoor residential cyfluthrin residues during a structured activity program. *J Expo Anal Environ Epidemiol* 2003, 13: 112-119.
5. He F, Wang S, Liu L, Chen S, Zhang Z, Sun J. Clinical manifestations and diagnosis of acute pyrethroid poisoning. *Arch Toxicol* 1989, 63: 54-58.
6. Tucker SB, Flannigan SA. Cutaneous effects from occupational exposure to fenvalerate. *Arch Toxicol* 1983, 54: 195-202.
7. Knox JM, Tucker SB, Flannigan SA. Paresthesia from cutaneous exposure to a synthetic pyrethroid insecticide. *Arch Dermatol* 1984, 120: 744-746.
8. Le Quesne PM, Maxwell IC, Butterworth S.T.G. Transient facial sensory symptoms following exposure to synthetic pyrethroids: a clinical and electrophysiological assessment. *Neurotoxicology* 1980, 2: 1-11.
9. Wilks MF. Pyrethroid-induced paresthesia--a central or local toxic effect? *J Toxicol Clin Toxicol* 2000, 38: 103-105.
10. Tucker SB, Flannigan SA, Ross CE. Inhibition of cutaneous paresthesia resulting from synthetic pyrethroid exposure. *Int J Dermatol* 1984, 23: 686-689.
11. Song JH, Narahashi T. Selective block of tetramethrin-modified sodium channels by (+/-)-alpha-tocopherol (vitamin E). *J Pharmacol Exp Ther* 1995, 275: 1402-1411.